

INTRODUCTION:

MRI-US fusion targeted biopsy is recommended in men with MRI visible lesions. For lesions not visible on MRI, or when fusion is inaccurate, the diagnostic performance of standard transrectal US is insufficient for prostate cancer lesions. This study aimed to evaluate the performance of a novel transrectal **micro-ultrasound** (micro-US) using high-frequency at **29 MHz (ExactVu™)** with an embedded fusion software.

METHODS:

- Retrospective analysis of consecutive men undergoing MRI-micro-US fusion targeted biopsy from May 2018 to March 2019.
- MRI lesions not visualised with micro-ultrasound, targeted with fusion imaging
- Standard US and micro-US was performed with suspicious lesions noted
- MRI-micro-US fusion targeted biopsy, followed by micro-US targeted biopsy, followed by random biopsy, as clinically indicated.
- Clinically significant disease: any **Grade 4** and/or **total cancer length ≥10mm**.

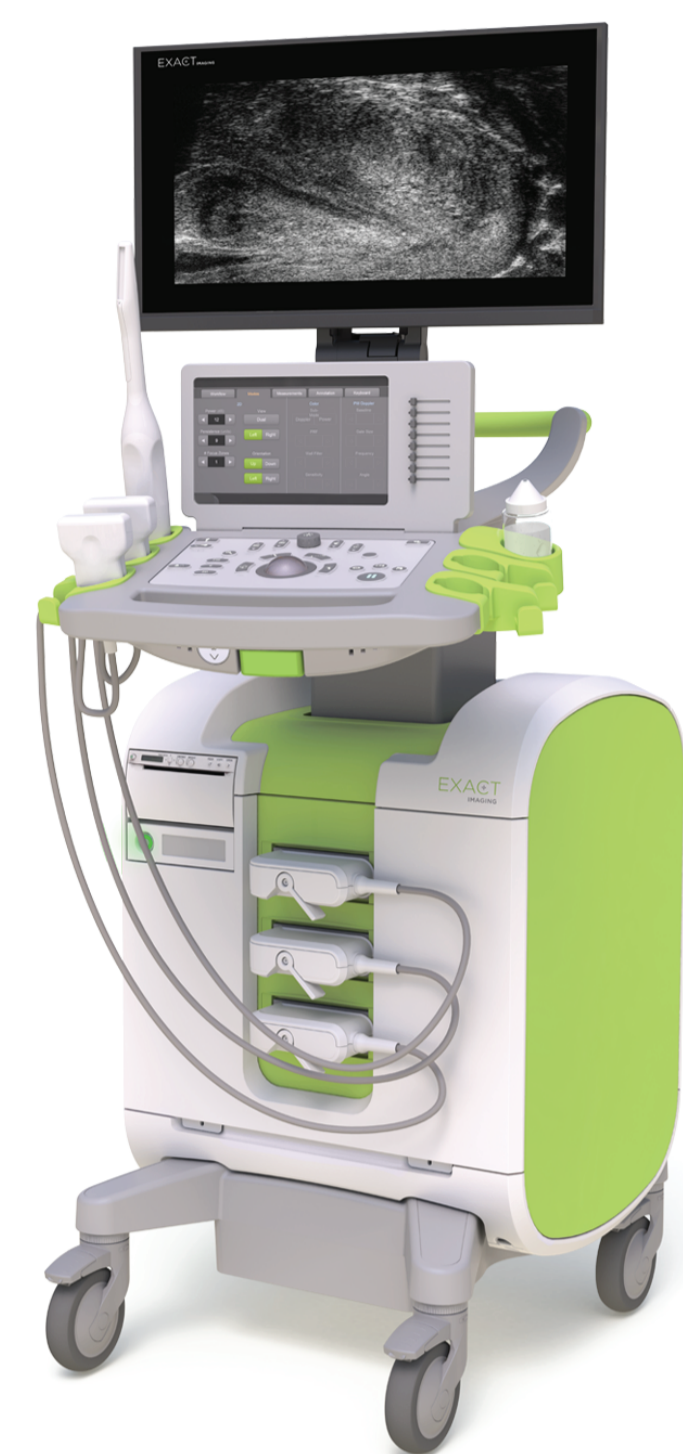


Figure 1: Exact Imaging's ExactVu™ 29 MHz Micro-Ultrasound System

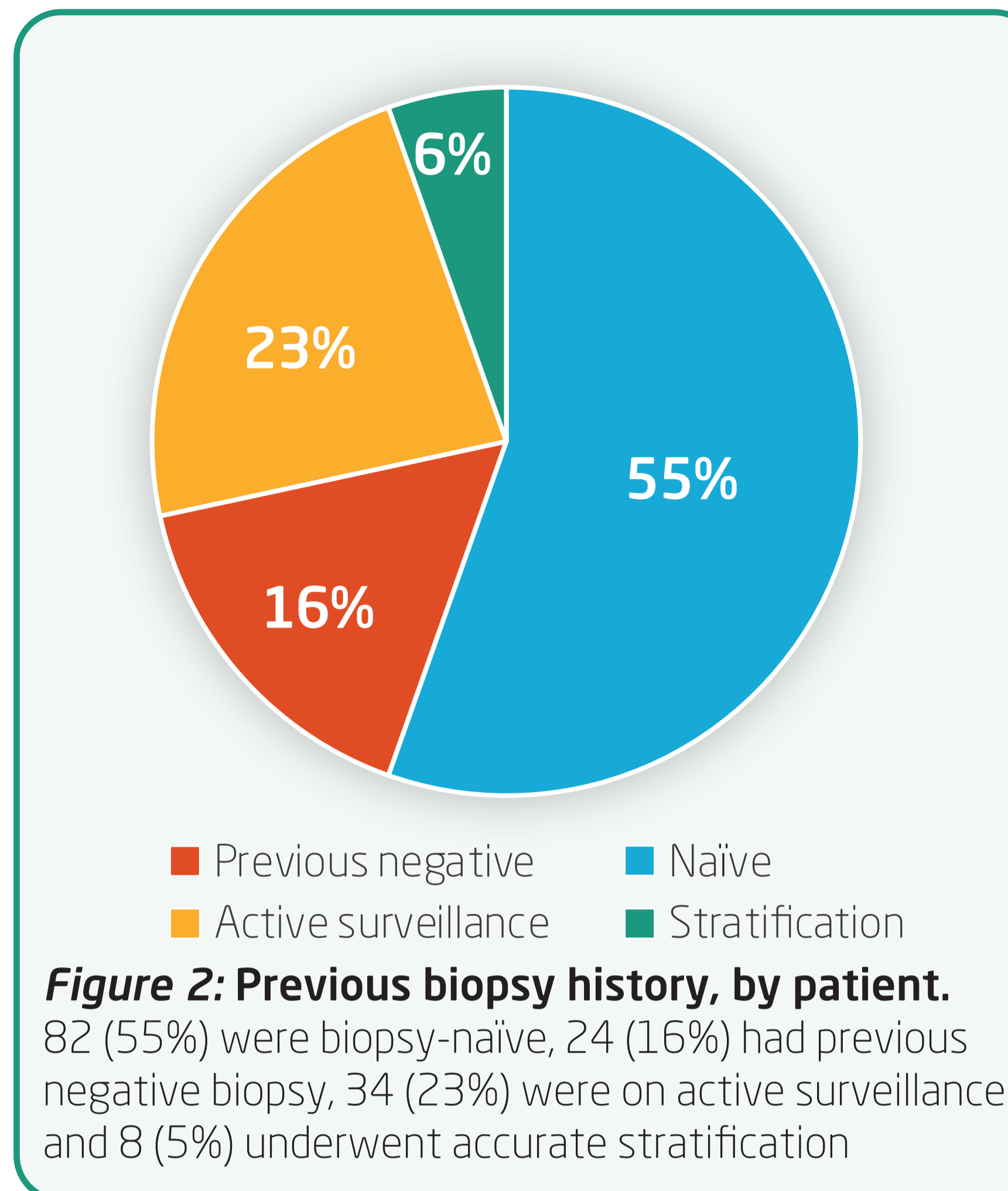


Figure 2: Previous biopsy history, by patient. 82 (55%) were biopsy-naïve, 24 (16%) had previous negative biopsy, 34 (23%) were on active surveillance and 8 (5%) underwent accurate stratification

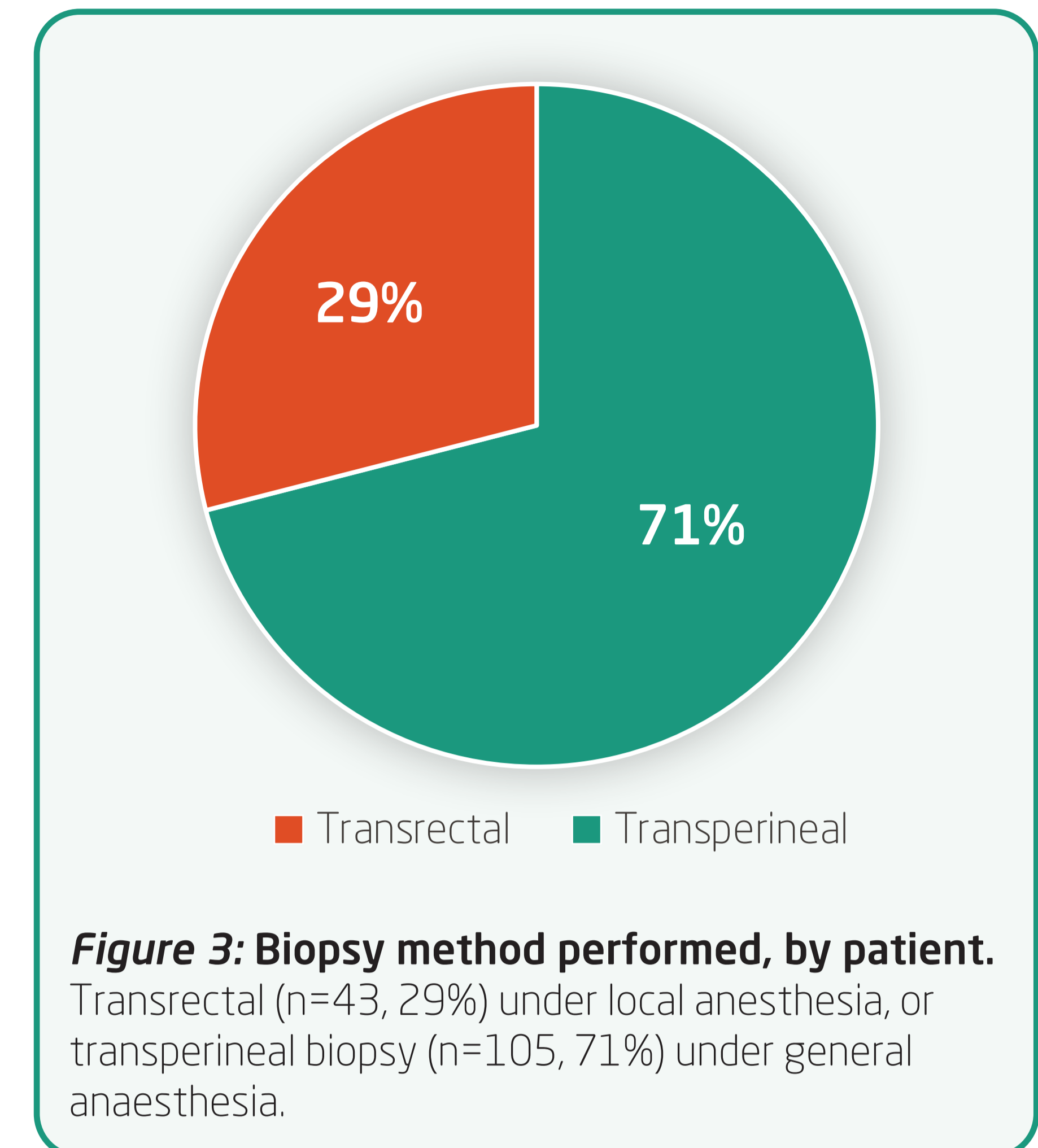


Figure 3: Biopsy method performed, by patient. Transrectal (n=43, 29%) under local anesthesia, or transperineal biopsy (n=105, 71%) under general anaesthesia.

Patients	148 included (19 excluded for incomplete imaging or previous treatment)
Age (years)	Mean 67 years (IQR 60-71)
PSA (ng/mL)	Mean 7ng/mL(4.6-10.4)
Number of Needles	Median 15 (12-21)
Number of Lesions	Mean 0.94 (± 0.72) for MRI , Mean 0.93 (± 0.66) for micro-US
Number of Positive Cores	Median 2 (0-6), maximum cancer core length of 6mm (4-9) and total cancer core length of 20mm (12-35)

Table 1: Patient population

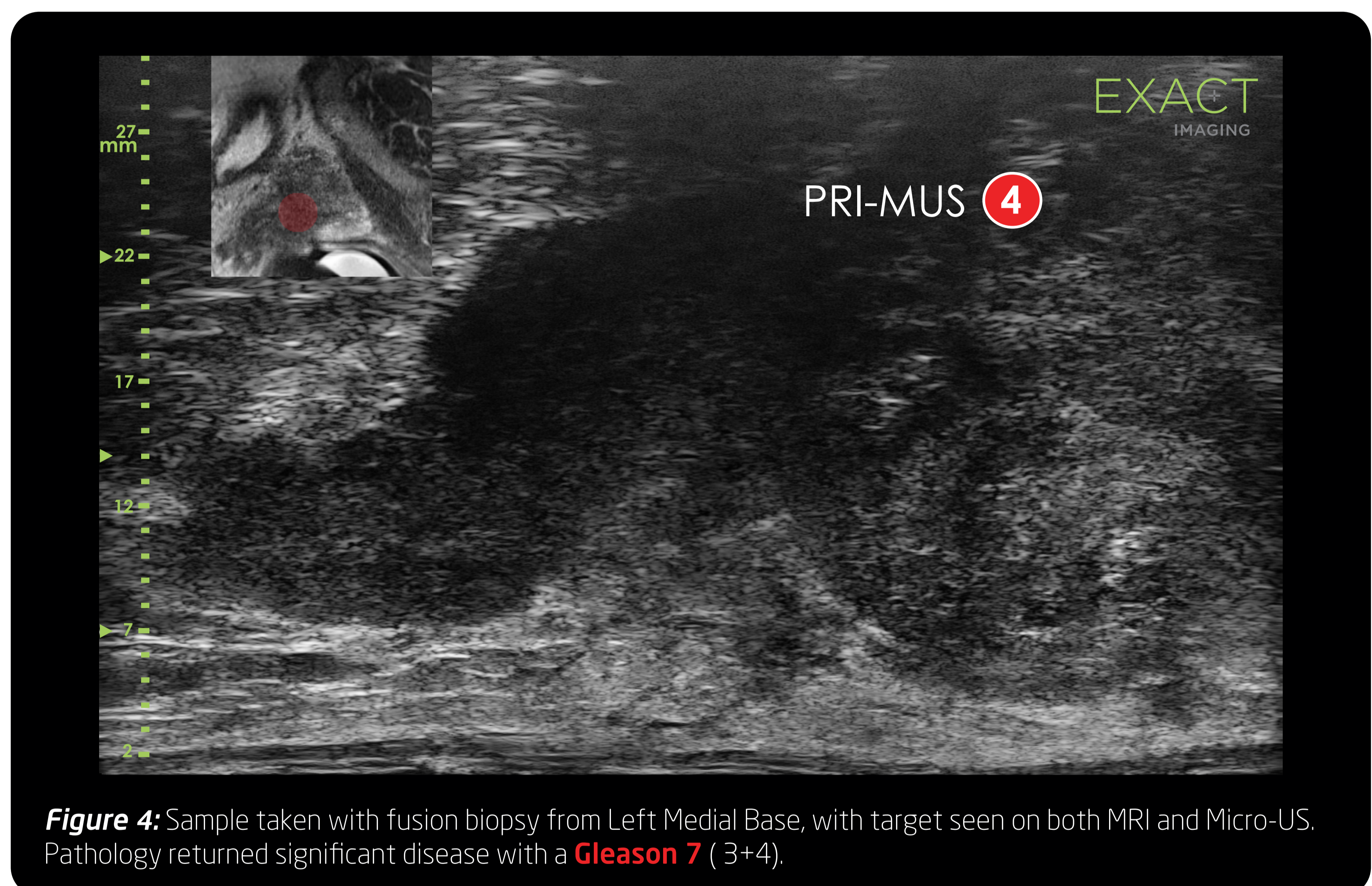


Figure 4: Sample taken with fusion biopsy from Left Medial Base, with target seen on both MRI and Micro-US. Pathology returned significant disease with a **Gleason 7** (3+4).

RESULTS:

- ▶ **Significant** disease was detected in **79** (53%), insignificant disease was detected in **14** (10%), no disease was detected in **55** (37%).
- ▶ Of the **88** posterior lesions **PI-RADS ≥ 3**, **66** (75%) were visible on micro-US.
- ▶ **36 MRI non-visible** lesions were **detected on micro-US**: **9** (25%) harboured significant, **8** (22%) harboured insignificant disease and 19 (53%) were false positive.

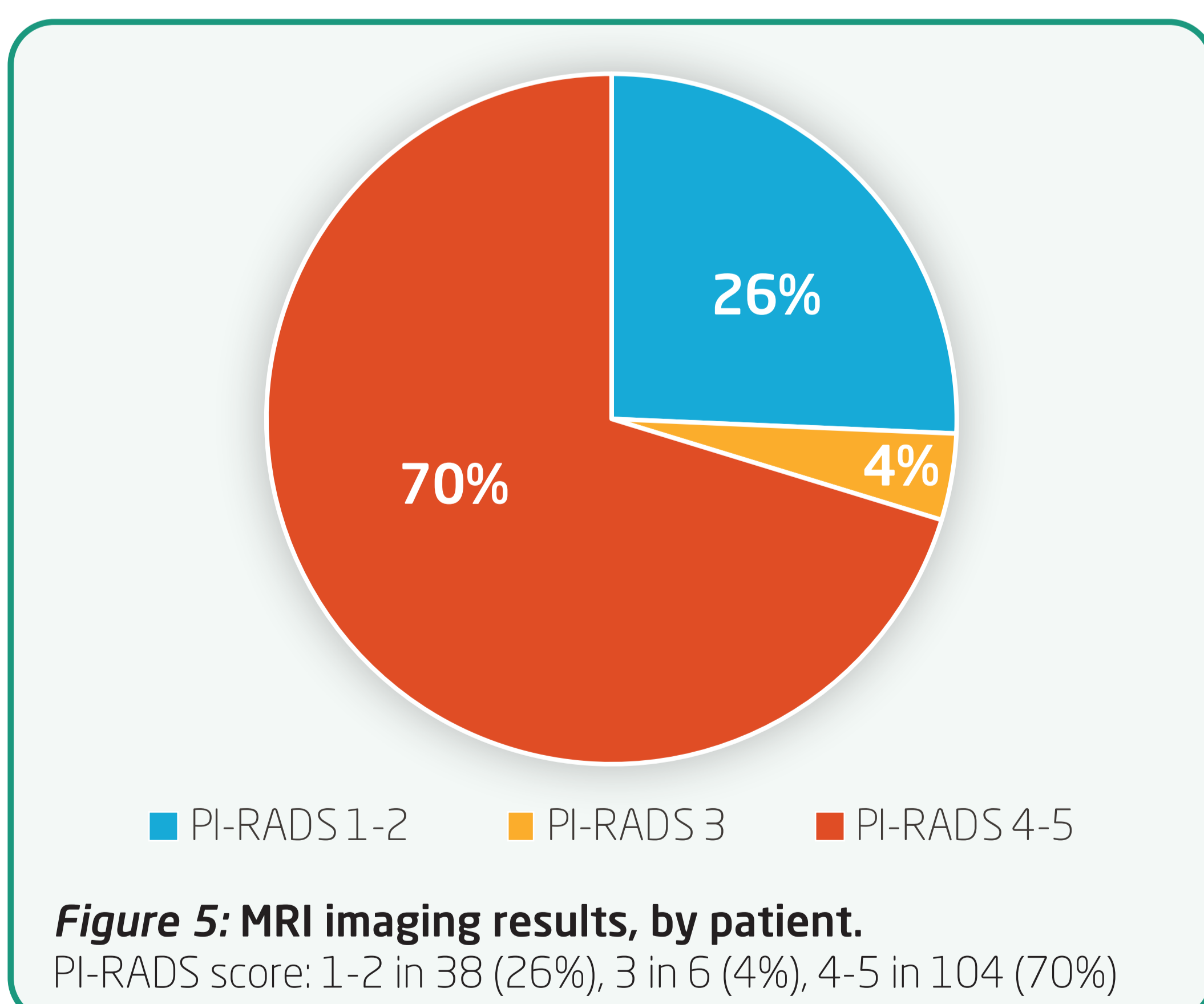


Figure 5: MRI imaging results, by patient. PI-RADS score: 1-2 in 38 (26%), 3 in 6 (4%), 4-5 in 104 (70%)

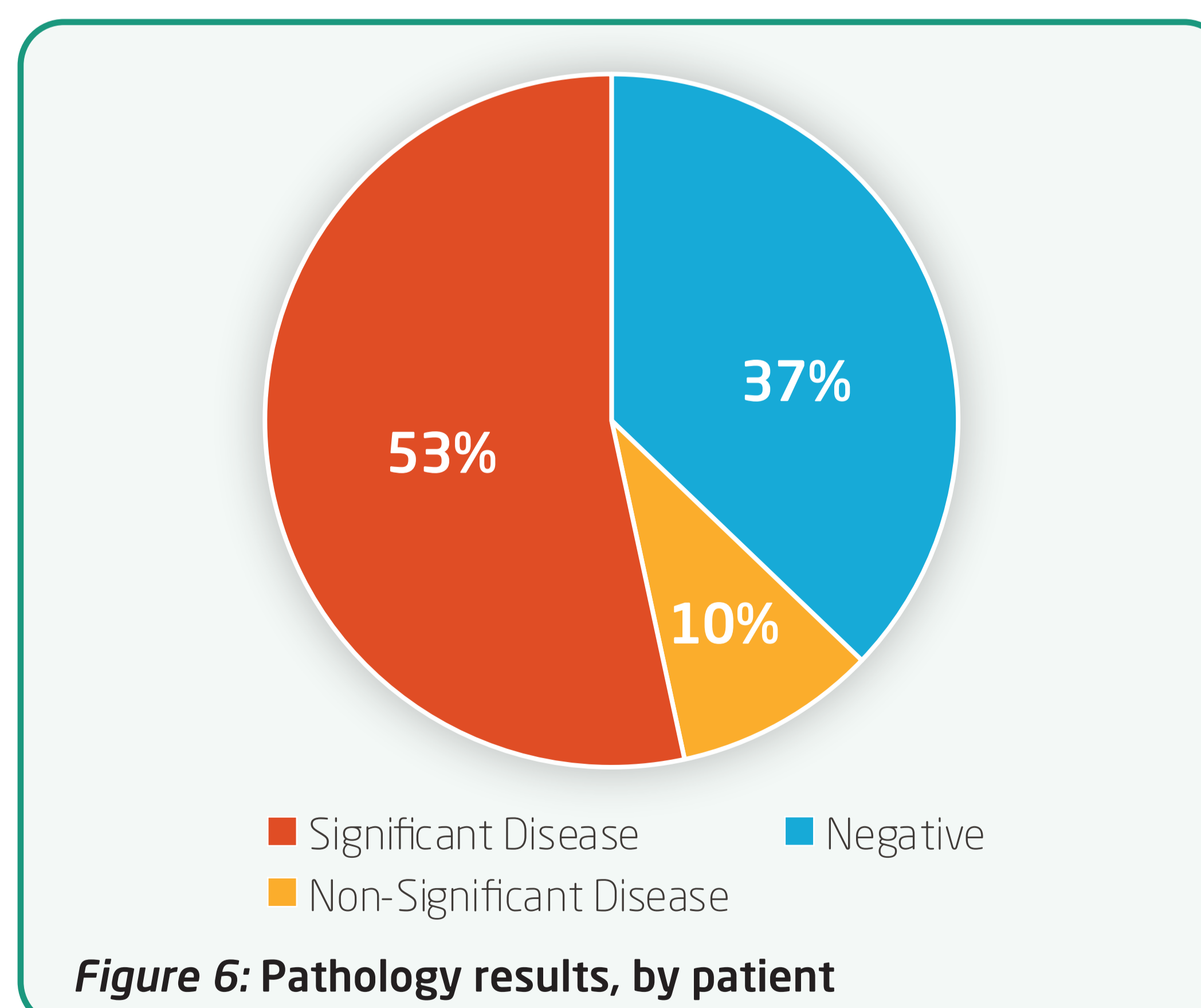


Figure 6: Pathology results, by patient

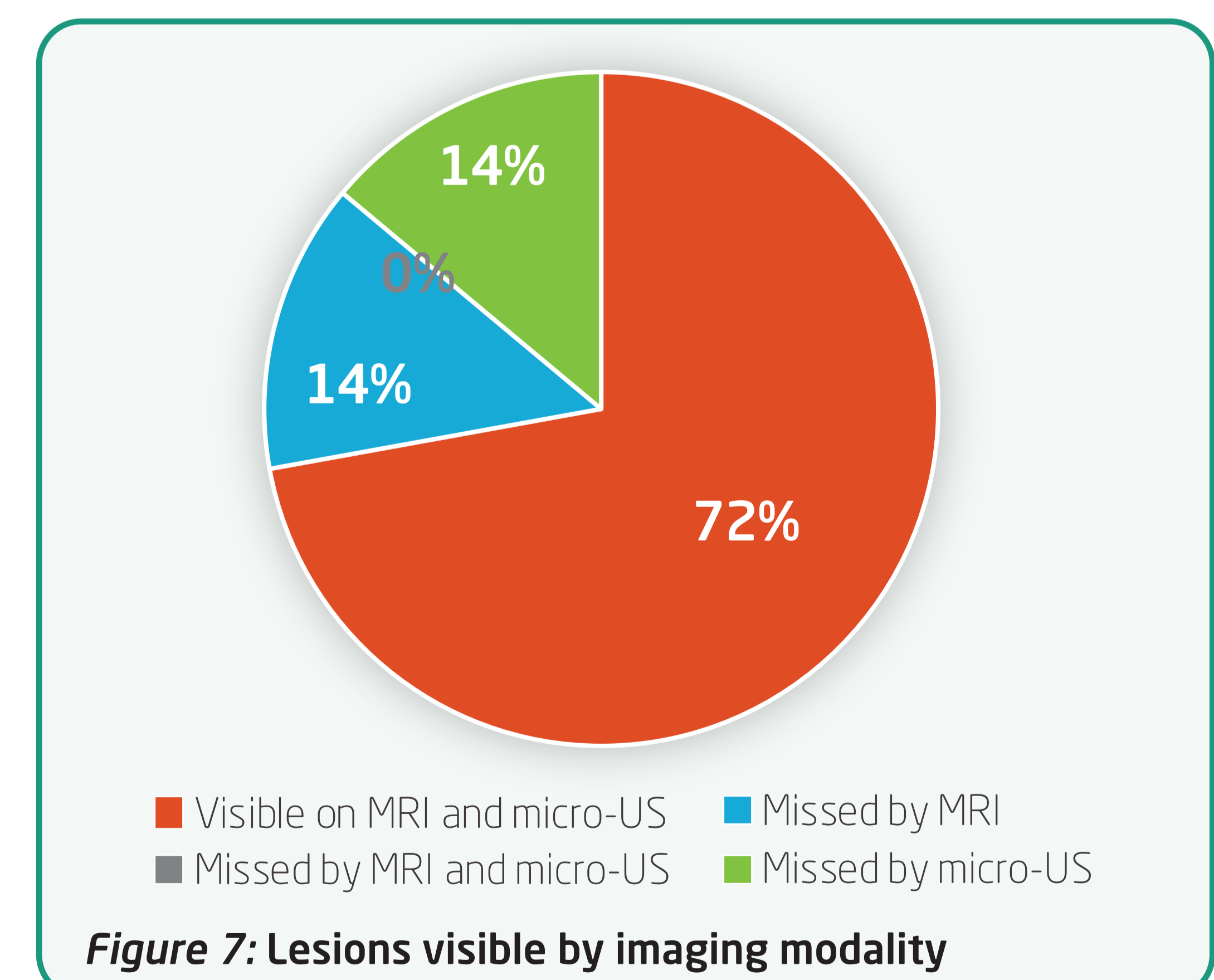


Figure 7: Lesions visible by imaging modality

CONCLUSIONS:

- ▶ This study suggests that combining micro-US with MRI fusion targeted biopsy might enhance the detection rate of significant disease.
- ▶ Most lesions are **visible** on **micro-US**, **minimizing** any **error** associated with **incorrect MRI fusion**.